

Pathomechanism of shock wave injuries on femoral artery, vein and nerve An experimental study in dogs

Ching-Jen Wang^{a,*}, Hsuan-Ying Huang^b, Kuender Yang^c, Feng-Sheng Wang^c, Mark Wong^a

^a Department of Orthopaedic Surgery, Chang Gung Memorial Hospital at Kaohsiung, 123, Ta Pei Road, Niao Sung Hsiang, Kaohsiung 833, Taiwan

^b Department of Pathology, Chang Gung Memorial Hospital, Kaohsiung Medical Centre, Kaohsiung 833, Taiwan

^c Department of Medical Research, Chang Gung Memorial Hospital, Kaohsiung Medical Centre, Kaohsiung 833, Taiwan

Accepted 20 December 2001

Abstract

Purpose: To study the pathomechanism of shock wave injuries to the femoral artery, vein and nerve in dogs.

Materials and methods: High-energy shock wave (0.47 mJ/mm² energy flux density) were applied to the right femoral artery, vein and nerve in nine mongrels, and the left side was used as control. Macroscopic examinations including structure integrity, edema, discoloration and extravasation; and microscopic examinations including detachment of the intima layer, disruption of the medium layer, capillary congestion, neutrophil margination and extravasation of the outer layer and the surrounding tissues were performed in 2 h, and in 4 days, respectively, after shock wave application.

Results: The most serious injuries included disruption of the medium layer with separation from the adventitia layer of the femoral artery. The injuries to the femoral vein and nerve predominantly involved the outer adventitia layer and the surrounding tissues. Mild nerve bundle swelling was noted in most cases. There were capillary congestion, neutrophil margination and extravasation indicative of inflammatory tissue reaction after shock wave application.

Conclusion: High-energy shock waves caused serious injuries to the femoral artery, vein and nerve, especially the femoral artery and inflammatory reaction to the surrounding tissues. © 2002 Elsevier Science Ltd. All rights reserved.

1. Introduction and background

Extracorporeal shock wave therapy is a widely accepted method of treatment in patients with urinary stones. Recently, shock waves had been used in the treatment of certain orthopaedic disorders [1–4]. The value of shock waves had been proven in the treatment of chronic non-unions of the long bone fractures with 75–88% success [1,5–8], and there is a positive effect in tennis elbow, painful heel and calcifying tendinitis of the shoulder [1–4]. More recently, shock waves have also shown positive effect in the treatment of avascular necrosis of the femoral head [9]. Shock wave treatments are associated with certain risks including injuries to the neurovascular structures adjacent to bone tissues. Shock wave therapy generally is not recommended in fractures near open epiphyses because of the potential for disrupting growth, and fractures near major neurovascular structures such as those in the spine, chest or skull because of potential damage to these structures. However, there has been no reported study on the magnitude and the mechanism of dam-

age to the major neurovascular structures caused by shock waves to our knowledge. The purpose of this study was to investigate the magnitude and the pathomechanism of shock wave injuries on the femoral artery, vein and nerve in dogs.

2. Materials and methods

This investigation was studied in nine mongrels with body weight ranging from 12 to 17 kg. The study was approved by the Institutional Review Board and was performed under the guidelines of the care and use of animals in research. The source of shock waves was from an OssaTron orthotripter (High Medical Technology, Kreuzlingen, Switzerland). The dogs were anaesthetised with intra-muscular ketamine (15 mg/kg) and intravenous pentobarbital (30 mg/kg). High-energy shock wave of 5000 impulses at 20 kV (equivalent to 0.47 mJ/mm² of energy flux density) was applied to the femoral artery, vein and nerve of the right groin. The left side received no shock wave and was used as control. The location of shock wave application was determined by palpation of the femoral artery, and the control guide of the shock wave machine determined the depth. Surgical lubrication gel was applied to the skin of

* Corresponding author. Tel.: +886-7-733-5279; fax: +886-7-733-5515.
E-mail address: w281211@adm.cgmh.org.tw (C.-J. Wang).

contact with the shock wave tube. Immediately after shock wave application, the right groin was examined for redness, swelling, edema, petechiae, hematoma or bleeding.

Five dogs were euthanised in 2 h after shock wave application. The femoral artery, vein and nerve from both groins were explored and the gross findings of these structures were carefully inspected. The macroscopic examination included structure integrity, discoloration, edema, extravasation, laceration or disruption. Then a 2 cm long specimens from the femoral artery, vein and nerve were removed for microscopic examination. The remaining four dogs were sacrificed 4 days after shock wave application and similar procedures were performed.

The biopsy specimens were kept in formaldehyde solution until microscopic sections were performed. The microscopic sections of the femoral artery, vein and nerve were stained with hematoxylin and eosin stain, and the nerve tissues were also stained with Luxol fast stain. The microscopic features examined included fragmentation or detachment of the intima layer, haemorrhage or disruption of the medium layer, separation or disruption between the medium layer and the adventitia layer, capillary congestion, neutrophil margination and extravasation of the surrounding tissues. The nerve fibres were also examined for swelling, separation and disruption as well as Schwann cell distribution.

The severity of injury was graded as mild, moderate and severe: mild injury was defined when the damaged area involved less than one-third of the structural circumference; moderate injury was defined when the injury involved more than one-third, but less than two-third of the circumference, and severe injury was defined when the injury involved more than two-third of the structural circumference. The degree of capillary congestion was graded as mild when the size of the capillary on the affected side is larger but less than twice of the control side; moderate when the size of capillary is twice of the control size, and severe when the capillary size is three times or larger than the control. The neutrophil margination was graded based on the number of neutrophils attached to the periphery of the capillary wall, and the neutrophil extravasation by the number of neutrophils scattered within the surrounding tissues. The swelling of nerve fibre was defined when there were vacuoles present between nerve bundles, and the degree of swelling was graded according to the number of vacuoles present. In addition, nerve fibres were examined for orientation and arrangement as well as Schwann cell distribution. The macroscopic and microscopic findings of the study group were examined with direct comparison with those of the control group.

3. Results

3.1. Macroscopic findings

In the control group, the femoral artery, vein and nerve showed grossly normal appearance with smooth surface and

normal elasticity. There was no evidence of swelling or haemorrhage and the structures were intact.

In the study group, none of the limbs showed ischaemic change after shock wave application. Two of the four dogs which were sacrificed in 4 days after shock wave application walked with a slight limp on the right leg, but there was no evidence of complete paralysis. The femoral artery, vein and nerve were structurally intact and none showed evidence of haemorrhage. The tissue elasticity appeared normal. There was no gross disruption, laceration or erosion. There was no discernable difference on the gross appearance of the five cases examined in 2 h as compared to those four cases examined in 4 days after shock wave application. However, local oedema and discoloration of the tissues were noted in all study cases.

3.2. Microscopic findings

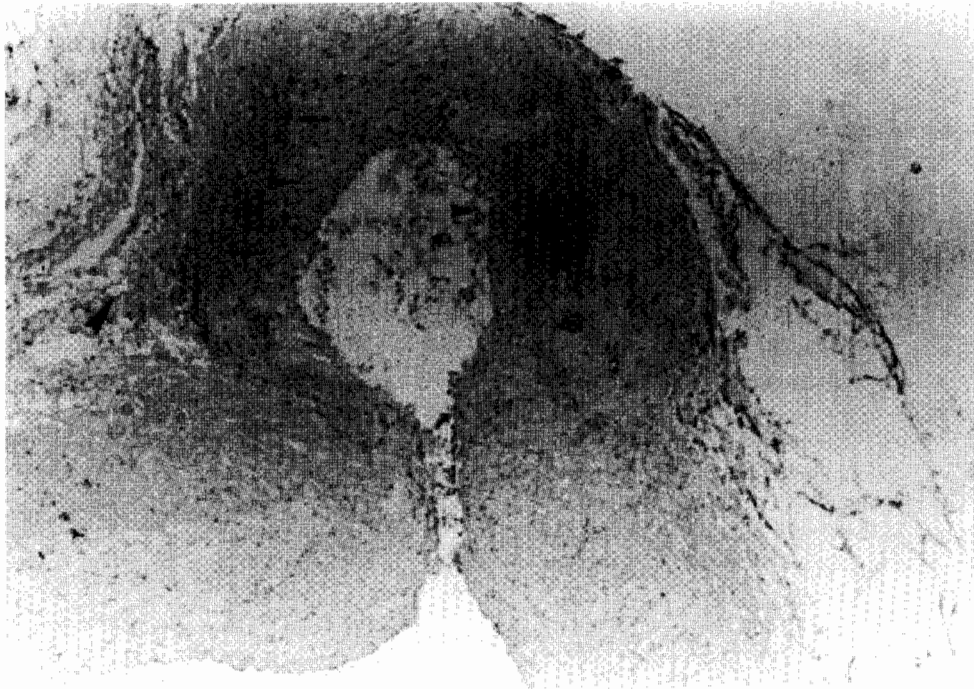3.2.1. Changes in femoral artery

The specimens of the control group showed intact arterial walls, which consist of gearwheel shaped intimal layer of elastic lamina, muscular medium layer and outer adventitial layer with normal surrounding tissues and capillaries. None of the specimens showed detachment, separation or disruption of the arterial wall or congestion of the surrounding tissues.

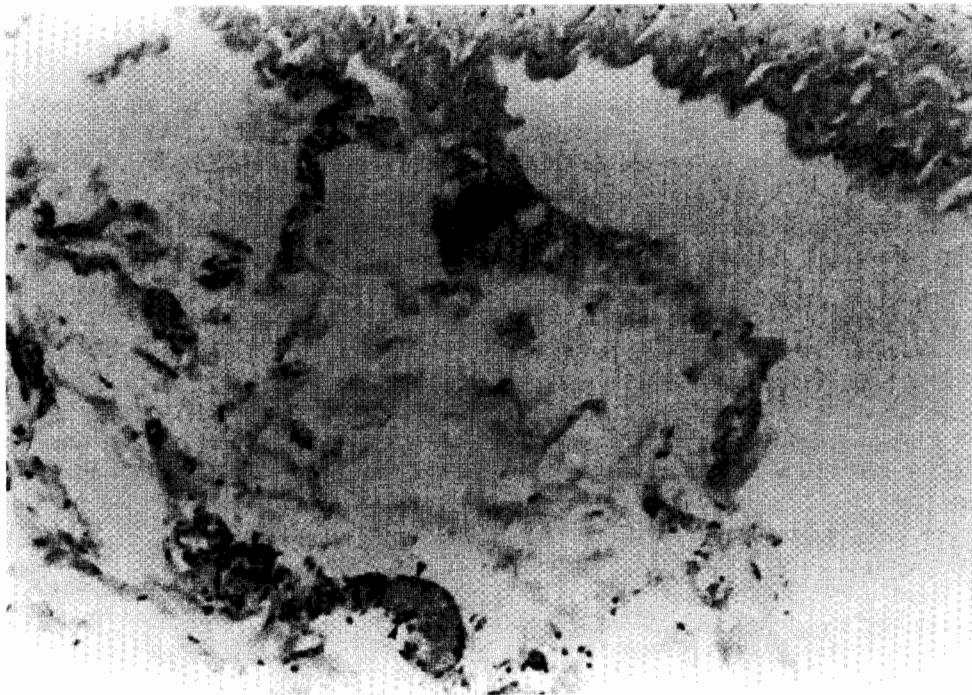
The specimens of the study group, however, showed damages in the intima layer in all cases with 1 severe, 3 moderate and 5 mild. The five cases obtained in 2 h after shock wave application showed 1 severe, 2 moderate and 2 mild damages; while those four cases obtained 4 days after shock wave application showed 1 moderate and 3 mild damages.

The damages to the medium layer were 3 severe, 6 moderate and none mild. Those five cases which were obtained in 2 h after the shock wave application showed severe damage in 2, moderate in 3 and none mild; and the other four cases which were obtained 4 days after shock wave application showed severe damages in 1 moderate in 3 and none mild. One case showed severe haemorrhage and disruption of the smooth muscles in the medium layer.

The injuries of the adventitia layer were severe in 1, moderate in 5 and mild in 3. The damage in the five cases obtained 2 h after shock wave application were 0 severe, 3 moderate and 2 mild; and the results of those four cases which were obtained 4 days after shock wave application were 1 severe, 2 moderate and 1 mild. One case also showed tissue necrosis. The capillary congestions were 0 severe, 6 moderate and 3 mild; and the neutrophil extravasation were 0 severe, 5 moderate and 4 mild. These changes were similarly distributed between specimens obtained at 2 h and 4 days after shock wave application. The most serious damage to the femoral artery occurred in the medium muscular layer. A typical case of injury to the femoral artery is shown in Fig. 1A and B.

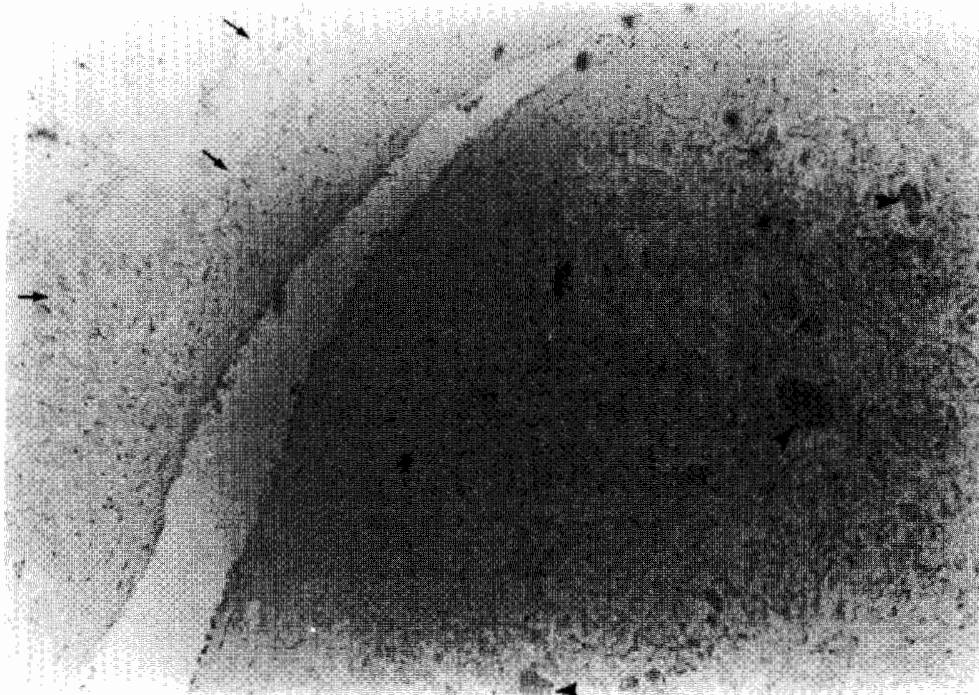


(A)

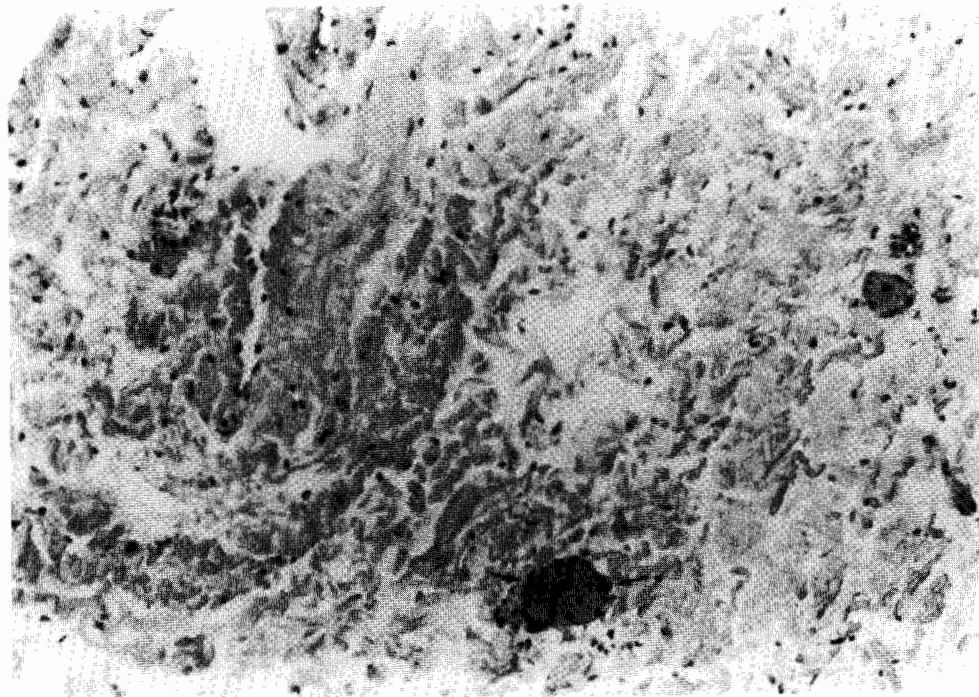


(B)

Fig. 1. (A) Microphotograph of a femoral artery showing focal intimal detachment (smaller arrowheads), medium layer disruption (arrows), and separation and disruption of the adventitia layer (large arrowheads) after shock wave application (hematoxylin–eosin stain $\times 50$); (B) microphotograph of the same specimen showing capillary congestion and neutrophil margination (arrowheads) (hematoxylin–eosin stain $\times 100$).

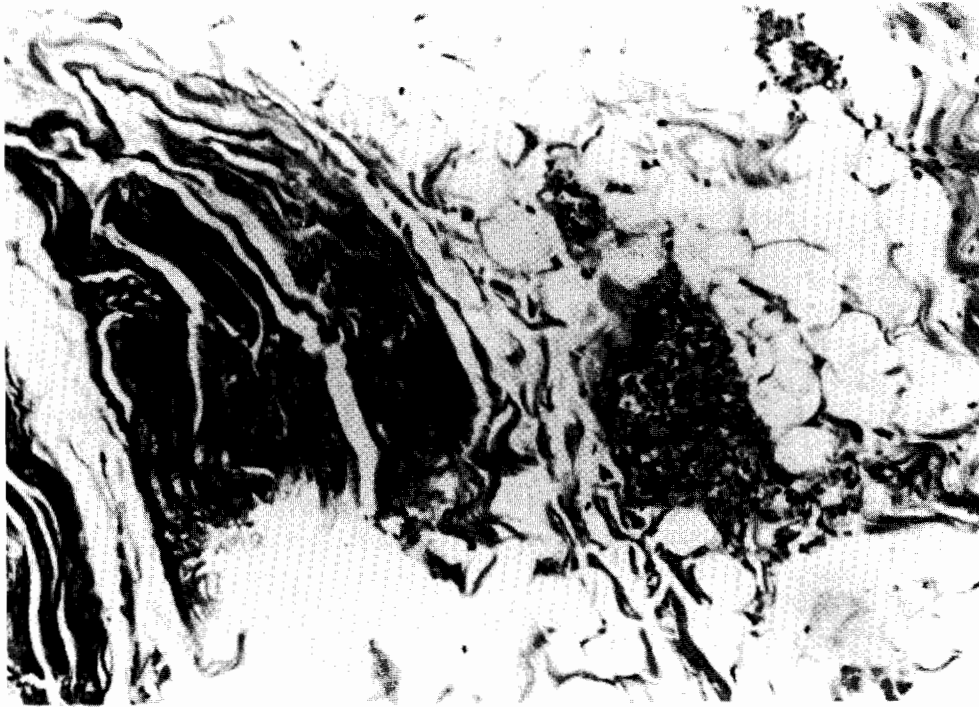


(A)

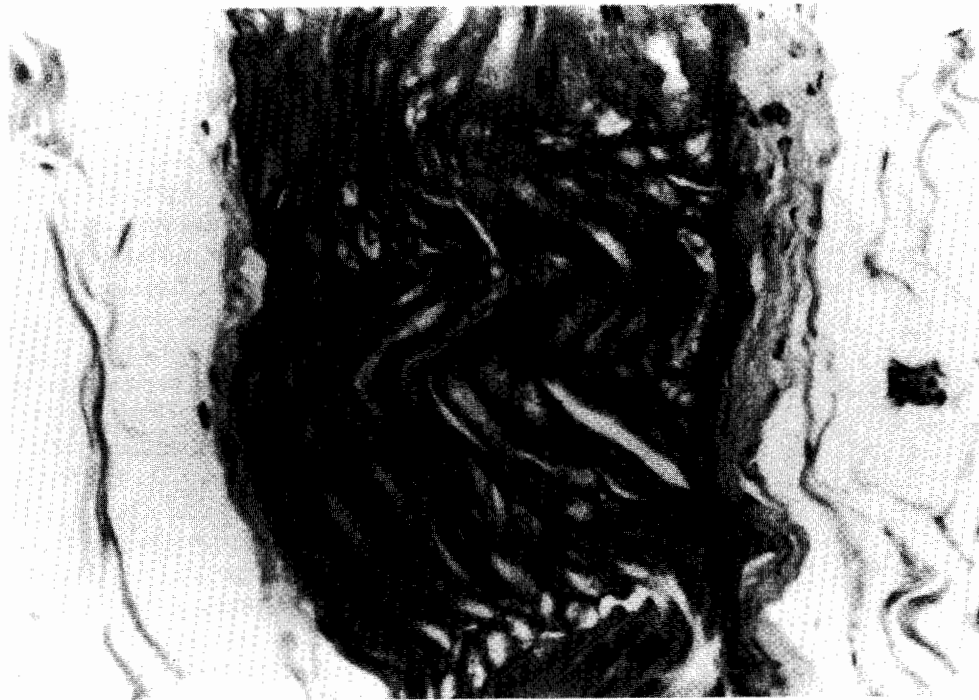

(B)

Fig. 2. (A) Microphotograph of a femoral vein showing intact intimal and medium layers with focal disruption of the adventitia (arrows) and capillary congestion (arrowheads) after shock wave application (hematoxylin-eosin stain $\times 50$); (B) microphotograph of the same specimen showing neutrophil margination (hematoxylin-eosin stain $\times 100$).



(A)



(B)

Fig. 3. (A) Microphotograph of a femoral nerve showing capillary congestion after shock wave application (Luxol fast stain $\times 50$); (B) microphotograph of the same specimen showing neutrophil margination (arrowhead) (Luxol fast stain $\times 50$).

3.2.2. Changes in femoral vein

The specimens of the control group showed normal histologic findings of an intact vein with well-preserved inner, medium and outer layers. None of the specimens showed swelling, edema or tissue disruption.

None of the specimens of the study group showed damages to the inner layer and the medium layer. However, all specimens showed injuries to the outer adventitia layer with 0 severe, 2 moderate and 7 mild. The injuries of the adventitia layer were similarly distributed between specimens obtained in 2 h and in 4 days after shock wave application. Two cases which were obtained in 4 days after shock wave application also showed neutrophil infiltration and this was probably related to surgical trauma.

The capillary congestion in the surrounding tissues were severe in 3, moderate in 4 and mild in 2; and the neutrophil margination and extravasation were 1 severe, 4 moderate and 4 mild. The damage to the femoral vein were more noticeable in the outer adventitia layer and the surrounding tissues. A representative case of injury to the femoral vein is shown in Fig. 2A and B.

3.2.3. Changes in femoral nerve

The specimens of the control group showed normal appearance of myelinated nerve fibres with Schwann cells. There was no capillary congestion, neutrophil extravasation, or vacuole present between the nerve bundles with Luxol fast stain.

Nerve fibre swelling was noted in eight of nine specimens of the study group with 0 severe, 1 moderate and 7 mild. The capillary congestions in the surrounding tissue were severe in 2, moderate in 5 and mild in 2; and the neutrophil margination and extravasation were 0 severe, 4 moderate and 5 mild. The damage to the femoral nerve were similar in both specimens which were obtained in 2 h and in 4 days, respectively, after shock wave application. The injuries to the surrounding tissues were more pronounced than injuries to the nerve fibres. A representative case of femoral nerve injury is shown in Fig. 3A and B. The details of microscopic findings of shock wave induced injuries to the femoral artery, vein and nerve are summarised in Table 1.

Table 1
Microscopic findings of shockwave induced injuries on femoral artery, vein and nerve

Anatomic area	Femoral artery	Femoral vein	Femoral nerve
Intima layer			
Severe	1 (11.1%)	0	NA
Moderate	3 (33.3%)	0	
Mild	5 (55.6%)	0	
None	0	9 (100%)	
Medium layer			
Severe	3 (33.3%)	0	NA
Moderate	6 (66.7%)	0	
Mild	0	0	
None	0	9 (100%)	
Adventitia layer			
Severe	1 (11.1%)	0	NA
Moderate	5 (55.6%)	2 (22%)	
Mild	3 (33.3%)	7 (88%)	
None	0	0	
Capillary congestion			
Severe	0	3 (33.3%)	2 (22.2%)
Moderate	6 (66.7%)	4 (44.4%)	5 (55.6%)
Mild	3 (33.3%)	2 (22.2%)	2 (22.2%)
None	0	0	0
Neutrophil margination/extravasation			
Severe	0	1 (11.1%)	0
Moderate	5 (55.6%)	4 (44.4%)	4 (44.4%)
Mild	4 (44.4%)	4 (44.4%)	5 (55.6%)
None	0	0	0
Nerve fibre swelling			
Severe	NA	NA	0
Moderate			1 (11.1%)
Mild			7 (77.8%)
None			1 (11.1%)

4. Discussion

The mechanism of shock wave therapy is not yet known. However, it was postulated that high-energy acoustic shock waves may cause microtrauma or microfracture and hematoma formation, which in turn, stimulate neovascularisation and enhance bone healing and relieve pain at the tendon–bone junction [1,7,10]. Both high and low energy shock waves have been used in the treatment of certain orthopaedic disorders [1–8,10]. Shock wave therapy is contraindicated in certain anatomic areas such as skull, chest and spine because of the potential risk of injury to the major structures [10–14]. The incidence of shock wave complications varied significantly with the location of treatment and the amount of shock wave energy [12–14]. High-energy shock waves can theoretically cause more serious injury to the neurovascular structures than low energy shock waves.

Some authors reported infrequent and low complications after shock wave therapy [2,11,12]. Fuchs et al. [12] stated that there is an impressively low incidence of complications related to the energy of shock wave. The severity and extent of damage are dose and pressure-dependent. Damage to nearby organs such as pulmonary, gastric, duodenal or colonic contusions, constitute a very infrequent complication. Elevation of liver enzymes was also noted after lithotripsy, but these changes are transient and have no significant clinical consequences. Loew and Jurgowski [2] reported marked reduction of symptoms and improvement in function of the shoulder with 2000 impulses of shock waves in patients with calcifying tendinitis of the shoulder. MRI did not show any lasting damage to bone or soft tissue. Carey and Strem [11] showed that the presence of an ipsilateral calcified aneurysm cannot necessarily preclude treatment of renal or upper ureteral calculi with extracorporeal shock wave lithotripsy.

Other studies, however, reported significant shock wave related injuries [12–14]. Knapp et al. [15] demonstrated an age-related positive linear correlation between post-therapeutic resistive index and patient age. Elderly patients have a higher risk of post-ESWL renal tissue damage. Rigatti et al. [13] demonstrated edema and extravasation of urine and blood into the interstitial spaces, blocking of cortical tubules by hemorrhagic streaks with signs of endothelial destruction and partial organisation of thrombi and abnormalities of the endothelium and glomerular epithelium, hemosiderin and patches of fibrosis after extracorporeal shock wave lithotripsy. Weber et al. [14] reported after 1000 shock waves at 18 kV lithotripsy in 20 patients, 15 (75%) showing gross evidence of marked vascular injury, only 5 (25%) normal or minimally affected. Gross interstitial haemorrhage (15/20), subcapsular haemorrhage (7/20) and haemorrhages into the renal pelvis (5/20) were confirmed. However, the nature of vascular injury and its mechanism by low energy shock waves were not described.

Shock wave therapy has been used in the treatment of certain orthopaedic disorders including chronic nonunions of the long bone fractures and avascular necrosis of the femoral head [1,5–9]. The application of shock wave is associated with the risk of injury to the neurovascular structures adjacent to bone. To our best knowledge, there has been no reported study on shock wave injuries to the neurovascular structures of the extremities. The results of the current study showed that high-energy shock waves caused severe injuries to the femoral artery including intima detachment and interstitial haemorrhage in dogs.

The findings of the current study showed that high-energy shock waves caused considerable damages to the major neurovascular structures including the femoral artery, vein and nerve. The severity of injury was more pronounced in the femoral artery than the femoral vein and nerve in that order. This was explained by the fact that femoral artery is firmer and less resilient than the femoral vein and nerve and is more susceptible to injury from shock wave application.

The injury to the femoral artery was most pronounced in the muscular medium layer. The disruption of the muscle layer may potentially weaken the arterial wall, and this further is compounded by the disruption and necrosis between the medium and the adventitia layers, and the risk of eventual aneurysm formation and catastrophic haemorrhage. The detachment of the intima layer may potentially cause thrombosis and occlusion of the artery. The capillary congestion, neutrophil margination and extravasation of the surrounding tissues clearly indicated an inflammatory tissue reaction due to shock wave application. Whether these injuries are reversible or not remains unanswered at the present time because none of the limbs from this study showed ischaemic changes. However, based on the microscopic findings the nature of injury suggests that the pathomechanism of shock wave induced injuries to the femoral artery is likely to be irreversible.

The injuries to the femoral vein were less severe, and they primarily involved the outer adventitia layer. The presence of capillary congestion, neutrophil margination and extravasation also confirmed an inflammatory tissue reaction of the femoral vein due to shock wave application.

Damage to the femoral nerve included moderately severe inflammatory tissue reaction with increased capillary congestion, neutrophil margination and extravasation of the surrounding tissues, and mild nerve fibre swelling in most cases. There was no gross disruption or distortion of the nerve bundles and alteration of Schwann cell distribution. None of the four dogs, which were sacrificed 4 days after shock wave application showed clinical evidence of femoral nerve paralysis.

In conclusion, high-energy shock waves caused serious damages to the femoral artery, vein and nerve, especially the femoral artery. The nature of injury suggests that the pathomechanism of shock wave induced injuries to these vital structures are likely to be progressive and irreversible. Therefore, shock waves are contraindicated in certain anatomic areas containing vital structures. In clinical application of shock wave therapy for orthopaedic disorders of the extremities, precautions must be made to avoid direct shock wave contact with the major structures including femoral artery, vein and nerve.

Acknowledgements

The authors thank Ms. Ya-Ju Yang and Ya-Hsueh Chuang for their technical assistance in this study.

References

- [1] Haupt G. Use of extracorporeal shock wave in the treatment of pseudoarthrosis, tendinopathy and other orthopaedic disease. *J Urol* 1997;158:4–11.
- [2] Loew M, Jurgowski W. Treatment of calcifying tendonitis of rotator cuff by extracorporeal shock waves: a preliminary report. *J Shoulder Elbow Surg* 1995;4(2):101–6.
- [3] Rompe J, Hope C, Kullmer K, et al. Analgesic effect of extracorporeal shock-wave therapy on chronic tennis elbow. *J Bone Joint Surg* 1996;78B(2):233–7.
- [4] Rompe JD, Hopf C, Nafe B, Burger R. Low-energy extracorporeal shock wave therapy for painful heel: a prospective controlled single-blind study. *Arch Orthop Trauma Surg* 1996;115(2):75–9.
- [5] Rompe JD, Eysel D, Hopf C, Vogel J, Kullmer K. Extracorporeal shockwave treatment of delayed bone healing, a critical assessment. *Unfallchirurg* 1997;100:845–9.
- [6] Schleberger R, Senge TH. Noninvasive treatment of long-bone pseudoarthrosis by shock wave (ESWL). *Arch Orthop Trauma Surg* 1992;111:224–7.
- [7] Valchanou V, Michailow P. High-energy shock waves in the treatment of delayed and nonunion of fracture. *Int Orthop* 1991;151:181–4.
- [8] Vogel J, Hoph C, Eysel P, et al. Application of extracorporeal shock waves in the treatment of pseudoarthrosis of the lower extremity: preliminary results. *Arch Orthop Trauma Surg* 1997;116:480–3.
- [9] Ludwig J, Lauber S, Lauber J, et al. Clinical and preliminary MRI results following high-energy extracorporeal shock-wave treatment (ESWT) of femoral head necrosis in adults. *Z Orthop* 1999;137(4): 2–5.

- [10] Rompe JD, Kirpatrick CJ, Kullmer K, Schwitalle M, Kirschek O. Dose-related effects of shock wave on rabbit tendo Achillis. A sonographic and histological study. *J Bone Joint Surg* 1998;80(3):546–52.
- [11] Carey SW, Strem SB. Extracorporeal shock wave lithotripsy for patients with calcified ipsilateral renal arterial or abdominal aortic aneurysms. *J Urol* 1992;148(1):18–20.
- [12] Fuchs GJ, David RD, Fuchs AM. Complications of extracorporeal shockwave lithotripsy. *Archivos Espanoles de Urologia* 1989;42 (Suppl 1):83–9.
- [13] Rigatti P, Colombo R, Centemero A, et al. Histological and ultra-structural evaluation of extracorporeal shock wave lithotripsy-induced acute renal lesions: preliminary report. *Eur Urol* 1989;16(3):207–11.
- [14] Weber C, Moran ME, Braun EJ, Drach GW. Injury of rat renal vessels following extracorporeal shock wave treatment. *J Urol* 1992;147(2):476–81.
- [15] Knapp R, Frauscher F, Helweg G, et al. Age-related changes in resistive index following extracorporeal shock wave lithotripsy. *J Urol* 1995;154(3):955–8.